



**VERSION I, 2018**



**GUIDELINES FOR MUSCULOSKELETAL SARCOMAS**

Till recently, interaction and exchange of views on sarcoma care in India was largely restricted to “single discipline” meetings organized by surgeons, pathologists, radiotherapists or medical oncologists individually with the occasional multidisciplinary meeting. The inception of the Indian Musculo Skeletal Oncology Society (IMSOS) with an aim to “promote scientific, evidence-based, comprehensive multidisciplinary management of bone and soft tissue sarcomas and encourage basic and clinical research” provided a common forum for interaction and mutual collaboration between different specialists involved in the treatment of sarcomas.

Sarcomas being rare, each individual or institution can only benefit from having access to pooled information and experience. Our socio-economic milieu being unique, IMSOS needs to take a leadership role in seeking to develop solutions and protocols suitable for our scenario while fostering training and education opportunities, promoting dissemination of knowledge and aiding in the development of locally applicable treatment guidelines for musculoskeletal sarcomas.

This brief monograph “IMSOS guidelines for musculoskeletal sarcomas” is a step in this direction. These guidelines are an attempt to standardise the management of musculoskeletal sarcomas in the country.

We have intentionally not elaborated on the specifics of drugs/dosages/surgical techniques, etc., but have suggested pathways that can be easily implemented with individual physician/institution modifications if desired. They are proposed in a manner which can be easily assimilated by medical students, community physicians and general specialists. This monograph is not intended to be a comprehensive textbook but recommendations that can be suitably modified with new information.

This is a preliminary venture by IMSOS and we hope to gradually expand on these guidelines over time. This monograph would not have been possible without the inputs and efforts of the IMSOS executive committee and numerous colleagues both national and international who contributed to the final version. IMSOS owes them a debt of gratitude.

The 12th Asia Pacific Musculoskeletal Tumor Society meeting in October 2018 at Jaipur, a joint meeting co-hosted with the Indian Musculo Skeletal Oncology Society (IMSOS) is an opportune moment to share these guidelines. The theme of the conference "Education – Collaboration - Innovation" epitomizes our desire to share and disseminate knowledge, the spirit of collaboration necessary to find answers to common problems and the need to derive innovative solutions best suited to our socio-economic milieu.

Helen Keller said, "Alone we can do so little; together we can do so much". This driving principle behind setting up IMSOS continues to inspire us in our endeavours to offer the best care to the maximum number of sarcoma patients.

**Prof. Ajay Puri**

President - Indian Musculo Skeletal Oncology Society

President - Asia Pacific Musculoskeletal Tumor Society

---

## IMSOS EXECUTIVE COMMITTEE

---

- **Prof. Ajay Puri** (President)
- **Dr. Ashish Gulia** (Secretary)
- **Dr. Mandip Shah** (Treasurer)
- **Dr. Bhavin Jankharia**
- **Dr. Yogesh Panchwagh**
- **Dr. Bhaskar Subin Sugath**
- **Dr. Girish Chinnaswamy**
- **Dr. Sujit Joshi**

## INDIAN MUSCULO SKELETAL ONCOLOGY SOCIETY (IMSOS) GUIDELINES

### MUSCULOSKELETAL SARCOMAS

- The IMSOS guidelines for musculoskeletal sarcomas represent the current thinking of national experts on the topic based on available evidence
- These guidelines are not intended to be a comprehensive review for treatment of these complex lesions but broad recommendations
- These guidelines do not bind a clinician to follow them. They merely suggest pathways that can be implemented with individual physician/institution modifications if desired
- As these guidelines are based on evidence that is continually evolving, they require periodical review and revision

Musculoskeletal sarcomas are relatively uncommon. The developments in the last few decades including advances in imaging, pathological classification, adjuvant modalities and surgical techniques have greatly improved not only the local management of these lesions but have also seen increased patient survival compared to earlier cases.

A clinical or radiological suspicion of a musculoskeletal sarcoma should result in a referral to a hospital / centre where there are specialists with the necessary expertise to diagnose and plan the management of these lesions (this need not be the ultimate treating centre though that would be the ideal scenario).

#### Suspicious signs suggestive of a sarcoma:

The commonest symptom of a primary bone sarcoma is non-mechanical pain. The presence of pain or a palpable mass arising from any bone should be viewed with suspicion. A plain X-ray in two planes is the first investigation of choice. The presence

of any of the following on the X-ray is suggestive, but not diagnostic of a bone sarcoma: (i) bone destruction, (ii) new bone formation, (iii) periosteal reaction and (vi) soft tissue swelling. Further investigation is then warranted.

The presenting symptoms and signs of soft-tissue sarcomas are nonspecific. They commonly present as a painless, slow-growing or occasionally rapidly growing mass. While sarcomas in the extremities may present earlier, diagnosis of sarcomas involving the pelvic cavity may be delayed. Their location deep within the body precludes palpation of the tumor mass early in the course of the disease. Consequently, these tumors often reach a large size prior to diagnosis without causing overt symptoms. Any soft tissue lump exhibiting any of the following clinical features should be considered to be malignant until proved otherwise: (i) increasing in size, (ii) size >5 cm, (iii) deep to the deep fascia, (iv) painful. The more of these clinical features present, the greater the risk of malignancy with increasing size being the best individual indicator.

An important dictum to follow would be that -

*“Any soft tissue mass found deep to the deep fascia or larger than 5 cm should be regarded as a soft tissue sarcoma until proven otherwise.”*



After a diagnosis is proposed based on the clinic-radiologic picture a biopsy is planned. Biopsy is to be done only after all local imaging is completed (refer to specific guidelines on page 14). Ideally the biopsy of a possible sarcoma should only be carried out at a tumor treatment centre. In case this is not possible a telephonic cross consult with an orthopaedic /surgical oncologist or an identified “tumor treatment” centre would help in planning the biopsy site. The goal is to obtain adequate material in an appropriate manner without compromising subsequent treatment and prognosis. A poorly performed biopsy may not only fail to provide a diagnosis; it may compromise limb salvage, lead to more extensive surgery than initially planned and have a negative impact on overall survival. In Ewing sarcoma and soft tissue tumors

immunohistochemistry confirmation of the histopathological diagnosis is desirable. Additional cytogenetic and molecular studies may also be necessary to reach a diagnosis in certain musculoskeletal tumors.



A sarcoma once diagnosed should be referred to an identified “tumor treatment” centre with the requisite multidisciplinary facilities for the integrated care of these lesions. Referral may be based on the patient’s preference and geographical location.



Treatment schedules involving multidisciplinary care as indicated are planned. Administration of adjuvant modalities (chemotherapy / radiotherapy) may be carried out at centres closer to the patient’s residence (based on the patient’s preference and geographical location) keeping in mind the logistics of time duration of non-surgical neoadjuvant and adjuvant treatment modalities. Chemotherapy and radiotherapy are important components of the treatment and should be carried out by appropriate specialists and not by the surgeon. Though orthopaedic/surgical oncology skills may not be widely prevalent, the facilities for adequate chemotherapy and radiotherapy are more easily accessed at multiple locations.

Unless an amputation is advised for oncologic clearance (this can be performed by the local surgeon based on the level recommended by the sarcoma management team), the patients should undergo definitive resection of their sarcoma by a surgeon trained in orthopaedic/surgical oncology with the adequate infrastructure available to handle these complex resections and reconstructions. Such facilities would include ready availability of allied specialties such as a plastic surgeon, vascular surgeon and occasionally a general surgeon and urosurgeon in case of pelvic tumors. A well-stocked blood bank and an adequately equipped intensive care unit are also necessary. An accredited bone bank is of benefit in oncologic reconstructions. Establishing and maintaining a formal bone bank requires especially trained personnel. Immediate post

operative rehabilitation should be ideally under the supervision of a rehabilitation expert who works in close conjunction with the operating team. Subsequently, a detailed rehabilitation schedule can be given to the patient to be carried out under the supervision of local rehabilitation personnel with further telephonic consultation if necessary.

Continuing adjuvant therapy (chemotherapy / radiotherapy) as indicated after surgery is critical to ensure overall disease control and patients must be explained the importance of the same. Surveillance after therapy at regular intervals is important. The logistics of the same can be worked out on a case by case basis after discussion with the patient, treating team and referring physician.



#### **Post Treatment Surveillance:**

There is limited published data supporting specific policies for follow-up of surgically treated patients. Relapses most often occur to the lungs. The risk assessment based on tumor grade, tumor size and tumor site may help in choosing the appropriate follow-up policy. High-risk patients generally relapse within 2–3 years (late relapses though uncommon are also possible), while low-risk patients may relapse later. Although the use of MRI to detect local relapse and CT to scan for lung metastases is likely to pick up recurrence earlier, it is yet to be demonstrated that this is beneficial to survival or cost-effective compared with clinical assessment of the primary site and regular chest X-rays. Local examination, chest and local imaging (X-ray for bone tumors, ultrasonography for soft tissue tumors) every 3 to 6 months for the first 2 years, every 6 months for the next 3 years and annually after year 5 are suggested. Extended surveillance is necessary to identify and address the potential late effects of surgery, radiation and chemotherapy for long-term survivors.

## IMAGING GUIDELINES FOR FOCAL BONE LESIONS

### Modalities

1. Radiographs
2. Magnetic Resonance Imaging (MRI)
3. CT Scan
4. Positron Emission Tomography (PET) / PET- CT

### Radiographs

Whenever a patient presents with a swelling and it appears that there may be bone involvement, the radiographs should be obtained in two planes perpendicular to each other to allow accurate evaluation of the pathology. The joint above and below should be included.

### MRI

#### I. Patient with a known focal bone lesion on a radiograph

- A. Start with a large field of view (FoV) study to include both limbs and the joint above and below in the body coil.
- B. If the lesion looks aggressive on the radiograph and will likely need surgery, then a whole limb survey is indicated to allow accurate measurements and to detect other lesions.
- C. Use a dedicated coil for the body part, e.g. knee coil if the lesion is around the knee or in the leg, etc.
  - a. STIR coronal or sagittal, whichever is the more appropriate plane
  - b. T1W in the same plane as the STIR

- c. T2W in the perpendicular plane – e.g. if the STIR and T1 are in the coronal plane, then the T2W should be in the sagittal plane
  - d. T1W and T2W axials
  - e. Dynamic contrast-enhanced study when appropriate
  - f. Fat-saturated T1W axial, coronal and sagittal, post-contrast
- D. Comments
    - a. Avoid fat-saturated pre-contrast sequences as they do not allow accurate characterization of tumor / lesion morphology, unless these are part of a specialized sequence (i.e. DIXON series)
    - b. A plain non-contrast scan may suffice if it is a follow-up scan
    - c. The entire lesion should be imaged with all its margins
  - E. Report format
    - a. Lesion location
      - i. Site (e.g. tibia, femur)
      - ii. Epiphysis, metaphysis, diaphysis
      - iii. Central medullary, juxta-medullary, cortical, juxta-cortical
    - b. Lesion size in all 3 planes. Also the position of the lesion from the nearest landmark, e.g. distal femur lesions – distance from the femoral articular surface to be measured
    - c. Lesion characteristics – hypointense, hyperintense, pattern of dynamic enhancement, etc.
    - d. Comparison with the radiographic findings and then a diagnosis / differential diagnosis that includes the radiographic appearance
  - F. Report Delivery
    - a. Films should be printed with not smaller than 20 on 1 and one sequence per film (e.g. one T1W sagittal – 20 or fewer images – 1 film)
    - b. The scale should be visible on the side on each image
    - c. All patients should be provided with a CD with all the sequences

## II. Patient without a known focal bone lesion on a radiograph

As in point I above. However, as the presence of a focal bone lesion is not known in advance

- A. The whole limb or whole bone screening will be done after the focal lesion / body part has been scanned.
- B. If the scan is being done as a routine knee or shoulder with fat-saturated PD or T2W sequences, then the protocol needs to be changed the moment the focal bone lesion is identified.
- C. Even if the need for contrast may not have been discussed in advance, all attempts should be made to get the contrast study done when appropriate.
- D. The radiologist must make all attempts to interpret the MRI in the context of the radiograph and insist on the radiograph being available.

### CT Scan

The indications are limited and would involve -

1. Staging for pulmonary metastasis
2. Patients with contraindication to MRI
3. Patients with metallic implants
4. For pre-surgical planning of complex bone lesions with or without angiography
5. High index of suspicion or an MRI diagnosis of osteoid osteoma
6. For establishing the nature of some equivocal chondroid lesions
7. Cortical involvement in some soft tissue lesions in close proximity with bone

A volume scan should be done through the area concerned. If an angiogram is not required, or if a contrast MRI has already been done, then a plain scan suffices. Else a contrast-enhanced study should be performed.

All images should be reconstructed as 1 mm images at 0.5mm intervals with sagittal and

coronal images as well.

Report format and delivery as in MRI – I: E & F above.

### PET Scan

The indications are limited and would include:

1. Staging and post-treatment evaluation of patients with osteosarcoma and Ewing sarcoma
2. Evaluation of patients with equivocal cartilage lesions in some settings
3. Looking for extent of disease and other lesions, in patients above the age of 45 and where there is a strong suspicion of metastases, myeloma and lymphoma

These scans should follow standard protocols of vertex to mid-thigh, to be extended to involve both lower limbs, in patients with myeloma and where the disease is in the lower limbs. The CT scan component may be with or without intravenous contrast depending on the investigations that have been done earlier and the actual indication.

Report format and delivery as in MRI – I: E & F above.

## TREATMENT OVERVIEW

Also refer specific guidelines:

Osteosarcoma : page 18 - 20

Ewing sarcoma : page 21 - 23

Chondrosarcoma : page 24 - 25

Soft tissue sarcomas : page 26 - 28

Biopsy plays a very vital part in the diagnostic workup of musculoskeletal tumors. It is important that a clinician knows how to obtain adequate material in the least traumatic way without jeopardizing subsequent local control of the tumor. A poorly placed biopsy incision, a poorly performed biopsy, or the complications of a biopsy make it difficult to salvage an extremity and, in some instances, may affect the survival of the patient. Biopsy should be regarded as the final diagnostic procedure, not as a shortcut to diagnosis. It should be performed after all the imaging studies have been performed. The optimum integration of clinical and radiographic information prior to biopsy has important implications for the diagnosis and is necessary for accurate pathologic interpretation.

*Ideally, the biopsy must be performed by or under the supervision of the surgeon who will be carrying out the final treatment.*

In most cases a core needle biopsy is adequate (it may need to be image-guided depending on anatomical location of lesion) though occasionally an open biopsy may be required. Regardless of the type of biopsy, its placement is critical. For appropriate placement of the biopsy, the surgeon needs to know the probable diagnosis and the extent of the tumor and should have established an operative plan prior to biopsy.

- **No** transverse incisions in the extremities because the site of the incision cannot be excised en bloc with the longitudinally directed segments of bone or musculoaponeurotic compartments. Therefore, a longitudinal biopsy incision must be used in the extremity.
- **Avoid** the major neurovascular structures because if they are contaminated during the biopsy they may have to be sacrificed during the definitive procedure that follows.

- **Avoid** inter-compartmental planes as these offer paths of least resistance and may increase the area of potential contamination through a hematoma during and after biopsy.
- **Do not** traverse a normal anatomical musculoskeletal compartment in order to reach a compartment that is involved by tumor, so that it will not be necessary to remove both compartments at the time of the definitive procedure.
- **Do not** biopsy through the adjacent joint.
- **Avoid** biopsying heavily calcified or ossified and necrotic areas.

If infection is a differential diagnosis it is advisable to send the samples taken for both, microbiological culture as well as histology. It is important to send the entire sample to one experienced pathologist for diagnosis. Do not split the sample / specimen. In case additional opinions are desired the blocks / slides may be circulated for an opinion.

### Surgery:

Surgery of the primary tumor should be performed only after adequate preoperative staging and planning in a multidisciplinary meeting. The goal is to achieve adequate oncologic clearance while retaining best possible function. Conventionally, quantitative parameters are used to define resection margins. A marrow margin of 2 - 3 cms as evaluated on the T1 weighted MRI image showing maximum tumor dimensions is usually considered adequate clearance in bone lesions whereas a 2 cm margin away from the tumor is what most surgeons would aim to achieve in soft tissue lesions. Due to anatomical constraints, it is not always possible to achieve these absolute distances. The margin can be quantitatively less in the case of resistant anatomic barriers, such as muscular fasciae, periosteum, joint capsule, tendon, tendon sheath, epineurium, vascular sheath and cartilage.



Decisions about the optimal surgical procedure (i.e. limb salvage or amputation) should be made on an individual case to case basis depending on various factors (patient age, tumor site, size, extent and response to neoadjuvant therapy). The type of surgical reconstruction will depend on patient and surgeon choice, experience and facilities available following discussion of the risks and benefits of different options.

If a patient with a suspected primary malignant tumor presents with a pathological

fracture, internal fixation is contraindicated. External splintage is the treatment of choice along with appropriate pain control. Adequate imaging and diagnostic procedures are undertaken. A pathological fracture can cause dissemination of tumor cells into the surrounding tissues and increase the risk of local recurrence. The options of local control are evaluated accordingly.

### **Chemotherapy:**

Multiagent chemotherapy is the standard of care in osteosarcoma and Ewing sarcoma. Doxorubicin, cisplatin, high-dose methotrexate and ifosfamide have demonstrated anti-tumor activity in osteosarcoma. Most current protocols incorporate these agents in 3 or 4 drug combinations. Agents considered most active in Ewing sarcoma include doxorubicin, cyclophosphamide, ifosfamide, vincristine, dactinomycin, and etoposide. Most current protocols are based on four to six drug combinations. The above chemotherapy combinations should be administered with adequate supportive care. Chemotherapeutic drugs may result in renal, cardiac, and auditory dysfunction in addition to common side effects like myelo-suppression, infection and neuropathy. Patients must therefore have baseline renal function testing and assessment of cardiac function as well as an audiogram (in case of treatment with cisplatin). Sperm banking is recommended for male patients of reproductive age while female patients would benefit with counseling by a fertility physician.

Currently there is inadequate evidence to recommend adjuvant chemotherapy as standard for all adult soft tissue sarcoma patients. It may be considered in a select population of high grade extremity sarcoma, > 5 cm or recurrent high-grade tumors using doxorubicin alone or a combination of doxorubicin plus ifosfamide. Any potential benefits should be considered in the context of the short and long-term toxicities of chemotherapy.

### **Radiotherapy:**

Osteosarcoma and chondrosarcoma are relatively radio-resistant; consequently radiotherapy has a limited role in these tumors. Radiotherapy is only used as definitive treatment of a primary tumor if there is no acceptable surgical option.

Ewing sarcoma being a radio-sensitive tumor, radiotherapy is utilized as part of management. It may be used as definitive local therapy if surgery is not an option, with curative intent or may be used in combination with surgery, for patients who have had a poor histological response to chemotherapy, or when there are concerns regarding adequacy of surgical resection. The dose administered depends on the resection margins and response to chemotherapy. Portals are individually tailored for the patient and radiotherapy target volumes based on pre-chemotherapy extent of the disease and include both, the bone and soft tissue component.

Radiotherapy has a definite role in the management of soft tissue sarcomas especially high grade tumors > 5 cms. Radiotherapy may be in the form of intraoperative brachytherapy, external beam radiotherapy or a combination of the two.

## OSTEOSARCOMA

Osteosarcoma is a primary malignant tumor in which the neoplastic cells produce osteoid matrix. It is the most frequent primary cancer of bone. The majority arise in adolescence, but some are linked to other pathologies (Paget's disease) occurring in the sixth and seventh decades of life. Osteosarcoma usually arises in the metaphysis of an extremity long bone, most commonly around the knee though it can occur anywhere in the axial or appendicular skeleton. Conventional osteosarcoma, a high grade malignancy, accounts for the majority of osteosarcoma. Other high grade types are telangiectatic, small cell, and high grade surface osteosarcoma. Low grade central and parosteal osteosarcoma are low grade malignancies, while periosteal osteosarcoma is an intermediate-grade osteosarcoma.

### Biopsy

- Biopsy diagnosis is mandatory
- Biopsy to be done only after all local imaging is completed
- In most cases a core needle biopsy is adequate (it may need to be image-guided depending on anatomical location of the lesion)

### Serological Investigations

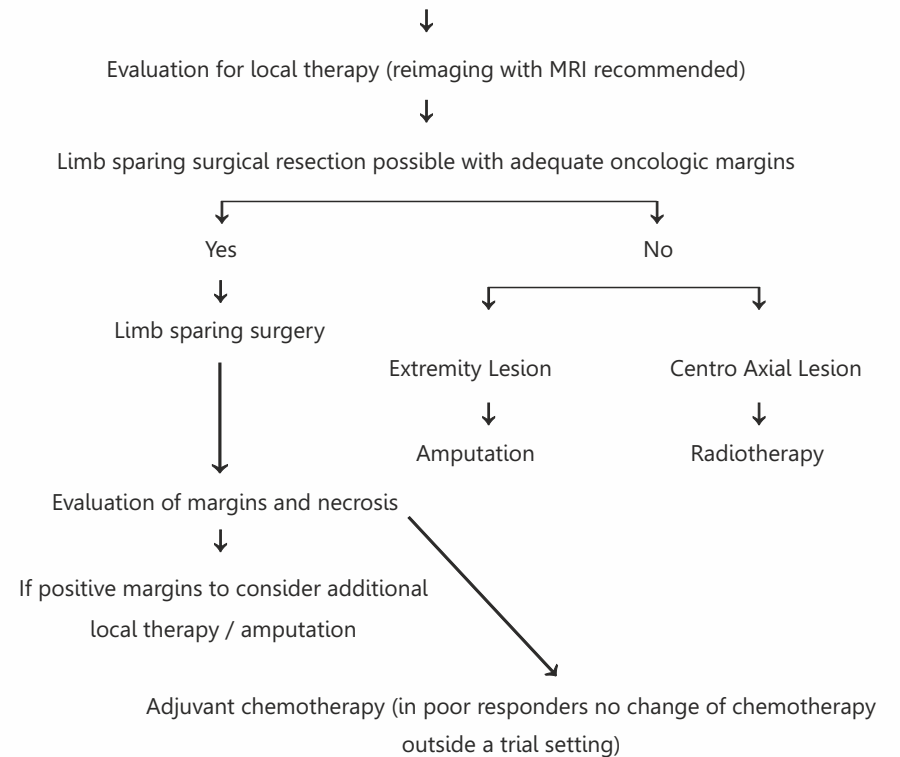
- Though there are no specific laboratory tests for diagnosis some may be of prognostic value; e.g. alkaline phosphatase (ALP) and lactate dehydrogenase (LDH)

### Staging

- Local X-Ray
- MRI
- CT Scan Chest
- Bone Scan

## HIGH GRADE OSTEOSARCOMA – NON METASTATIC AT PRESENTATION

Neoadjuvant chemotherapy - Doxorubicin, cisplatin, high-dose methotrexate and ifosfamide have demonstrated antitumor activity in osteosarcoma. Most current protocols incorporate these agents in 3 or 4 drug combinations.

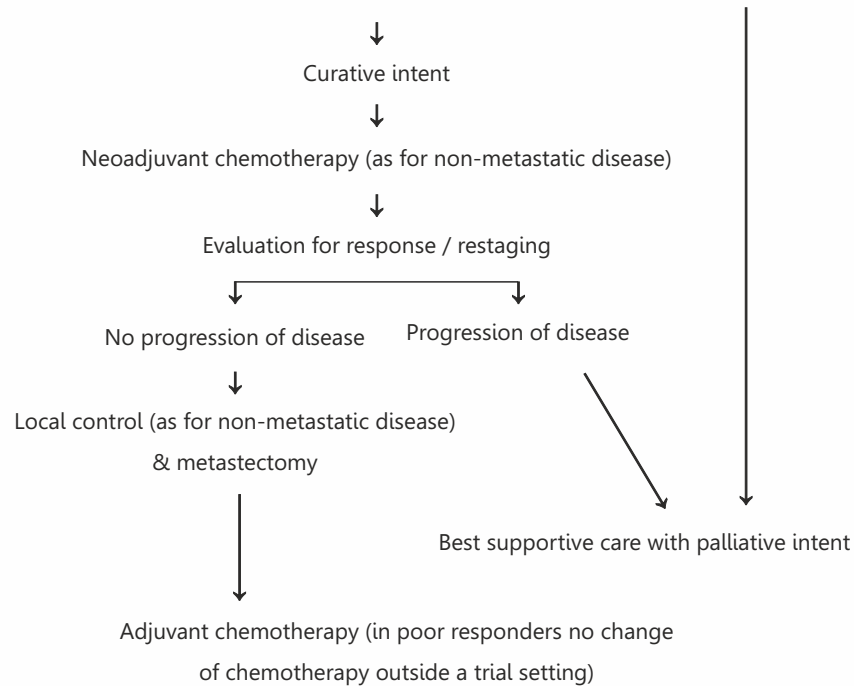


**Osteosarcomas diagnosed as low grade on initial biopsy (parosteal / low grade intramedullary) are treated with wide excision only. If after definitive surgery a high grade component is identified they receive multiagent adjuvant chemotherapy.**

**Periosteal osteosarcomas are currently treated similar to high grade osteosarcomas though the evidence for chemotherapy is not as robust as in high grade osteosarcomas.**

## HIGH GRADE OSTEOSARCOMA – METASTATIC AT PRESENTATION

To evaluate for intent of treatment based on site and number of metastasis



## EWING SARCOMA

Ewing sarcoma (including primitive neuroectodermal tumor of bone / PNET) is the second-most common primary malignant bone cancer in children and adolescents, but is also seen in adults. The most frequent sites of involvement are the long bones and pelvis. All forms of Ewing sarcoma are high grade tumors

### BIOPSY

- Biopsy diagnosis is mandatory
- Biopsy to be done only after all local imaging is completed
- In most cases a core needle biopsy is adequate (it may need to be image-guided depending on anatomical location of the lesion)
- Immunohistochemistry confirmation desirable, may need additional cytogenetic and molecular studies

### SEROLOGICAL INVESTIGATIONS

- Though there are no specific laboratory tests for diagnosis some maybe of prognostic value; e.g. alkaline phosphatase (ALP) and lactate dehydrogenase (LDH)

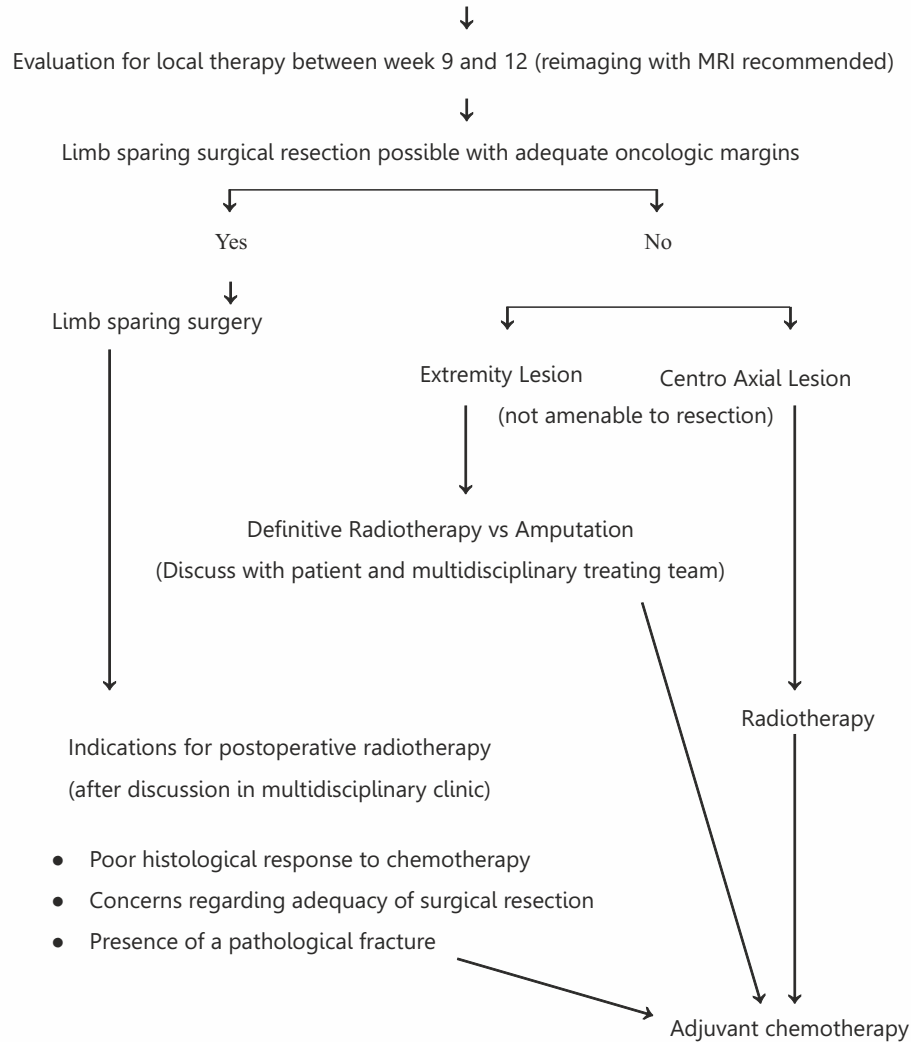
### STAGING

- Local X-Ray
- MRI
- PET CT Scan. If PET not available Bone Scan + CT Thorax & Bone Marrow aspiration & biopsy

## EWING SARCOMA – NON METASTATIC AT PRESENTATION

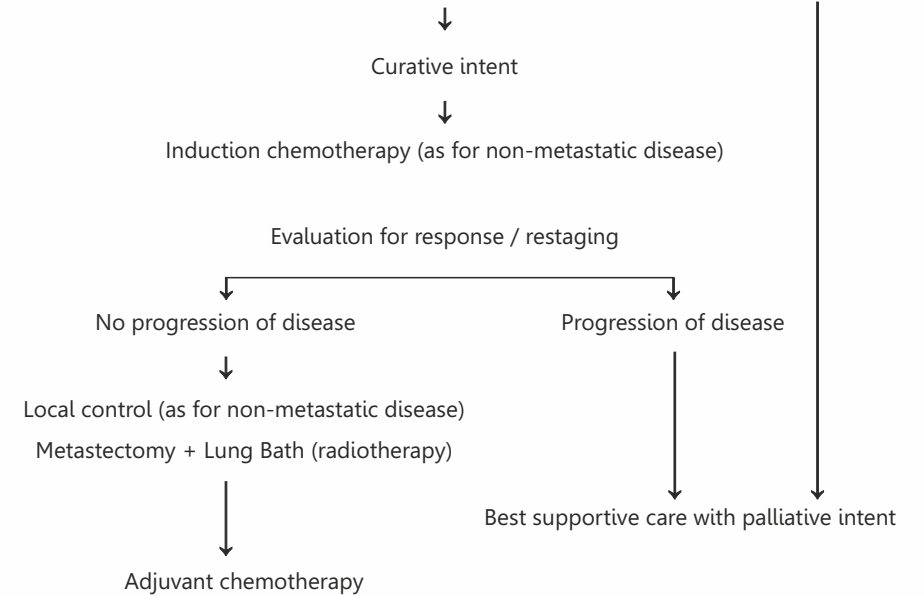
Induction chemotherapy - Agents considered most active in Ewing sarcoma include doxorubicin, cyclophosphamide, ifosfamide, vincristine, dactinomycin, and etoposide.

Most current protocols are based on four to six drug combinations.



## EWING SARCOMA – METASTATIC AT PRESENTATION

To evaluate for intent of treatment based on site and number of metastasis



## CHONDROSARCOMA

Chondrosarcoma is one of the most common bone sarcomas of adulthood, characterized by the production of tumor cartilage. Though commonest in the long bones they also occur in flat bones such as the pelvis, rib, and scapula. Secondary chondrosarcomas can arise in preexisting benign lesions such as osteochondroma and enchondroma. Rarer subtypes of chondrosarcoma include mesenchymal chondrosarcoma and clear cell chondrosarcoma. Conventional chondrosarcomas may rarely "dedifferentiate" into a very high grade tumor with a dismal prognosis, so called dedifferentiated chondrosarcoma.

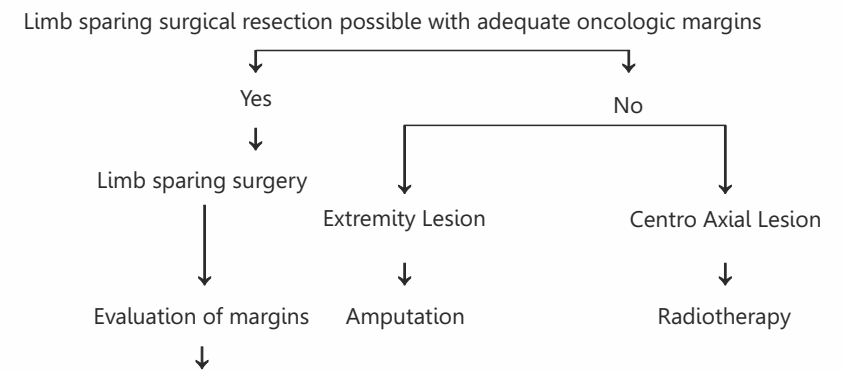
### BIOPSY

- Biopsy diagnosis is mandatory
- Biopsy to be done only after all local imaging is completed
- In most cases a core needle biopsy is adequate (it may need to be image-guided depending on anatomical location of the lesion)

### STAGING

- Local X-Ray
- MRI
- CT Scan Chest
- Bone Scan

## CHONDROSARCOMA



If positive margins to consider additional local therapy / amputation

**Though the benefit is not certain-**

- **Dedifferentiated chondrosarcomas may receive multiagent chemotherapy similar to high grade osteosarcoma.**
- **Mesenchymal chondrosarcoma may receive multiagent chemotherapy similar to Ewing sarcoma.**

**It may be feasible to safely treat extremity grade I (low grade) chondrosarcoma with intralesional curettage without increasing the risk for local recurrence or metastatic disease**

## ADULT SOFT TISSUE SARCOMAS

Soft tissue sarcomas are a rare and heterogeneous group of tumors representing less than 1% of all adult malignancies. Sixty percent of soft-tissue sarcomas occur in the extremities making them the commonest site.

### BIOPSY

- Biopsy diagnosis is mandatory
- Biopsy to be done only after all local imaging is completed
- In most cases a core needle biopsy is adequate ( it may need to be image-guided depending on anatomical location of lesion)
- Immunohistochemistry confirmation desirable, may need additional cytogenetic and molecular studies

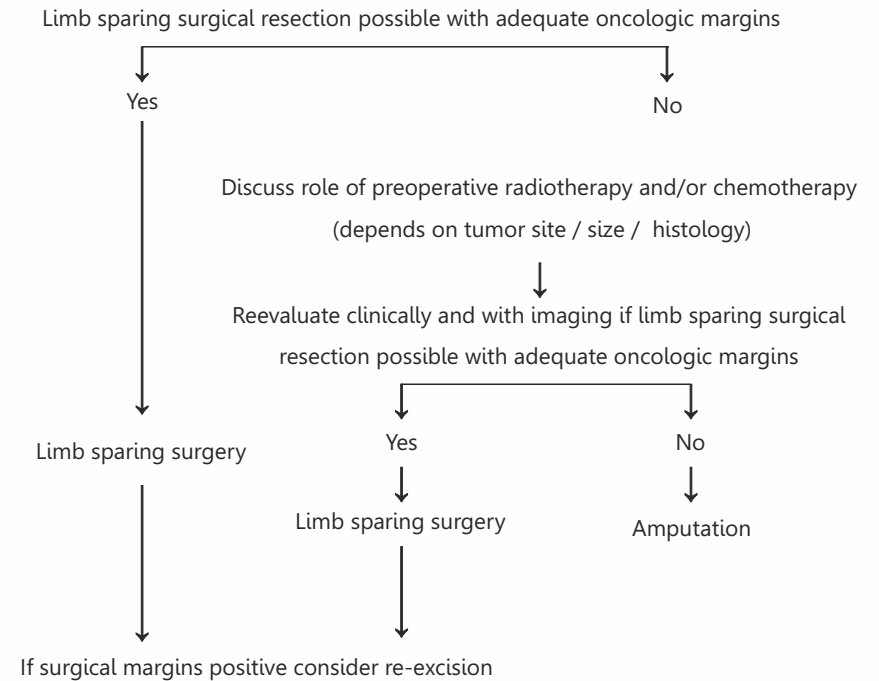
### STAGING

- Local X-Ray
- MRI
- X-Ray Chest / CT Scan (CT chest recommended in high grade sarcomas)
- Ultrasonography of abdomen pelvis (consider abdomino-pelvic CT) in myxoid / round cell liposarcoma, angiosarcoma, leiomyosarcoma, epithelioid sarcoma and synovial sarcoma
- Consider MRI spine for myxoid / round cell liposarcoma
- Consider CNS imaging for alveolar soft part sarcoma and angiosarcoma

**Tumors referred after prior excision with inadequate or unknown margins need to be considered for re-excision with similar guidelines as primary tumors.**

**Radiotherapy may be delivered either as pre or postoperative radiotherapy depending on surgeon/institution preference.**

## EXTREMITY SOFT TISSUE SARCOMAS – NON METASTATIC AT PRESENTATION



### Indications for radiotherapy

- High grade lesions
- Recurrent lesions
- Deep seated /or  $\geq 5\text{cm}$  /or margin +

**Chemotherapy may be offered to patients with high grade lesions  $> 5\text{cm}$  or recurrent lesions after discussion in multidisciplinary clinic (preferably in a trial setting)**



